

PennHIP Report

Referring Veterinarian: Dr James Bell

Clinic Name: Animal Medical Clinic
Castroville

Email: castrovilleamc@yahoo.com

Clinic Address: 8223 FM 471 S
Castroville, TX 78009

Phone: (830) 931-9439

Fax:

Patient Information

Client: Thomas, Renay

Tattoo Num:

Patient Name: Conan Haus Frbis

Patient ID: 33745

Reg. Name: Conan Haus Frbis

Registration Num: CORA 6135-21-119

PennHIP Num: 172263

Microchip Num: 642099010036202

Species: Canine

Breed: GERMAN SHORTHAIRED POINTER

Date of Birth: 05 May 2021

Age: 11 months

Sex: Male

Weight: 60 lbs/27.2 kgs

Date of Study: 14 Apr 2022

Date Submitted: 18 Apr 2022

Date of Report: 20 Apr 2022

Findings

Distraction Index (DI): Right DI = 0.23, Left DI = 0.29.

Osteoarthritis (OA): No radiographic evidence of OA for either hip.

Cavitation/Other Findings: No cavitation present.

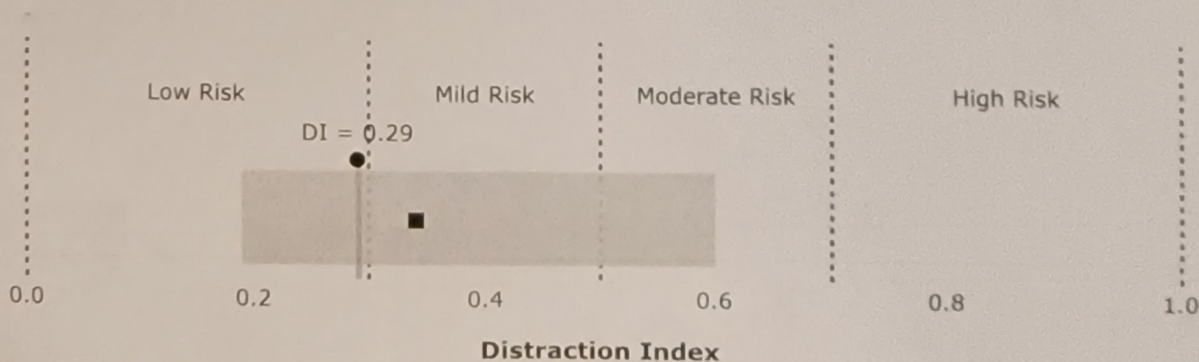
Interpretation

Distraction Index (DI): The laxity ranking is based on the hip with the greater laxity (larger DI). In this case the DI is 0.29.

OA Risk Category: The DI is less than or equal to 0.30. This patient is at minimal risk for hip OA.

Distraction Index Chart:

GERMAN SHORTHAIRED POINTER



BREED STATISTICS: This interpretation is based on a cross-section of 1585 canine patients of the GERMAN SHORTHAIRED POINTER breed in the AIS PennHIP database. The gray strip represents the central 90% range of DIs (CI)