

PennHIP Report

Referring Veterinarian: Dr James Bell

Clinic Name: Animal Medical Clinic
Castroville

Email: castrovilleamc@yahoo.com

Clinic Address: 8223 FM 471 S
Castroville, TX 78009

Phone: (830) 931-9439

Fax:

Patient Information

Client: Thomas, Renay

Tattoo Num:

Patient Name: Hennessy Von Magic City

Patient ID: 33541

Reg. Name: Hennessy by Von Magic City

Registration Num: GS-022139

PennHIP Num: 171001

Microchip Num: 956000012099198

Species: Canine

Breed: GERMAN SHORTHAIRED POINTER

Date of Birth: 13 Mar 2020

Age: 24 months

Sex: Female

Weight: 65 lbs/29.5 kgs

Date of Study: 15 Mar 2022

Date Submitted: 22 Mar 2022

Date of Report: 24 Mar 2022

Findings

Distraction Index (DI): Right DI = 0.23, Left DI = 0.30.

Osteoarthritis (OA): No radiographic evidence of OA for either hip.

Cavitation/Other Findings: No cavitation present.

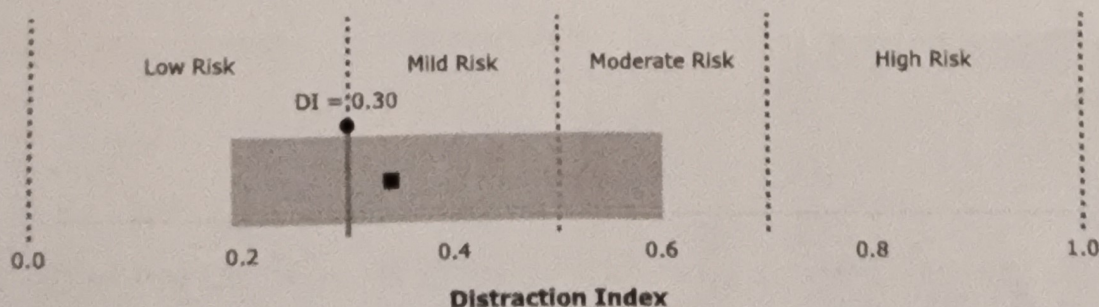
Interpretation

Distraction Index (DI): The laxity ranking is based on the hip with the greater laxity (larger DI). In this case the DI used is 0.30.

OA Risk Category: The DI is less than or equal to 0.30. This patient is at minimal risk for hip OA.

Distraction Index Chart:

GERMAN SHORTHAIRED POINTER



BREED STATISTICS: This interpretation is based on a cross-section of 1585 canine patients of the GERMAN SHORTHAIRED POINTER breed in the AIS PennHIP database. The gray strip represents the central 90% range of DIs (0.19 - 0.60) for the breed. The breed average DI is 0.34 (solid square). The patient DI is the solid circle (0.30).

SUMMARY: The degree of laxity (DI = 0.30) falls within the central 90% range of DIs for the breed. This amount of hip laxity places hip at a minimal risk to develop hip OA. No radiographic evidence of OA for either hip.