

PennHIP Report

Referring Veterinarian: Dr James Bell	Clinic Name: Animal Medical Clinic Castroville
Email: castrovilleamc@yahoo.com	Clinic Address: 8223 FM 471 S Castroville, TX 78009
	Phone: (830) 931-9439
	Fax:

Patient Information

Client: Thomas, Renay	Tattoo Num:
Patient Name: Arrow Summetra	Patient ID: 34043
Reg. Name: Arrow Summetra	Registration Num: GS 023520
PennHIP Num: 175512	Microchip Num: 203003000586396
Species: Canine	Breed: GERMAN SHORTHAIRED POINTER
Date of Birth: 23 Aug 2020	Age: 22 months
Sex: Female	Weight: 56 lbs/25.4 kgs
Date of Study: 24 Jun 2022	Date Submitted: 24 Jun 2022
Date of Report: 25 Jun 2022	

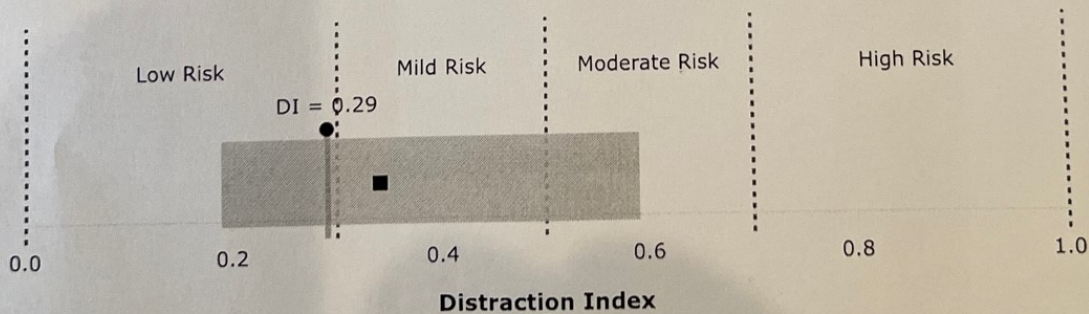
Findings

Distraction Index (DI): Right DI = 0.27, Left DI = 0.29.
 Osteoarthritis (OA): No radiographic evidence of OA for either hip.
 Cavitation/Other Findings: No cavitation present.

Interpretation

Distraction Index (DI): The laxity ranking is based on the hip with the greater laxity (larger DI). In this case the DI used is 0.29.
 OA Risk Category: The DI is less than or equal to 0.30. This patient is at minimal risk for hip OA.
 Distraction Index Chart:

GERMAN SHORTHAIRED POINTER



BREED STATISTICS: This interpretation is based on a cross-section of 1622 canine patients of the GERMAN SHORTHAIRED POINTER breed in the AIS PennHIP database. The gray strip represents the central 90% range of DIs (0.19 - 0.59) for the breed. The breed average DI is 0.34 (solid square). The patient DI is the solid circle (0.29).