AIS PennHIP

(877) 727-6800 www.antechimagingservices.com

*For best printing results please use Chrome
Owner's C

PennHIP Report

Referring Veterinarian: Dr James Bell

Email: castrovilleamc@yahoo.com

Clinic Name: Animal Medical Clinic Castroville

Clinic Address: 8223 FM 471 S
Castroville, TX 78009

Phone:

Fax:

Patient Information

Client: THOMAS, Renay
Patient Name: GENO VON DEM FEUERHAUS
Reg. Name: GENO VON DEM FEUERHAUS
PennHIP Num: 202915
Species: Canine
Date of Birth: 01 Dec 2022
Sex: Male
Date of Study: 04 Jun 2024
Date of Report: 06 Jun 2024

Tattoo Num:
Patient ID: AKC SS41427001
Registration Num: SS41427001
Microchip Num: 900235000462866
Breed: GERMAN SHORTHAIRED POINTER
Age: 18 months
Weight: 79 lbs/35.8 kgs
Date Submitted: 04 Jun 2024

Findings

Distraction Index (DI): Right DI = 0.20, Left DI = 0.20.
Osteoarthritis (OA): **No radiographic evidence of OA for either hip.**
Cavitation/Other Findings: No cavitation present.

Interpretation

Distraction Index (DI): The laxity ranking is based on the hip with the greater laxity (larger DI). In this case the DI us
0.20.
OA Risk Category: The DI is less than or equal to 0.30. This patient is at minimal risk for hip OA.
Distraction Index Chart:

GERMAN SHORTHAIRED POINTER

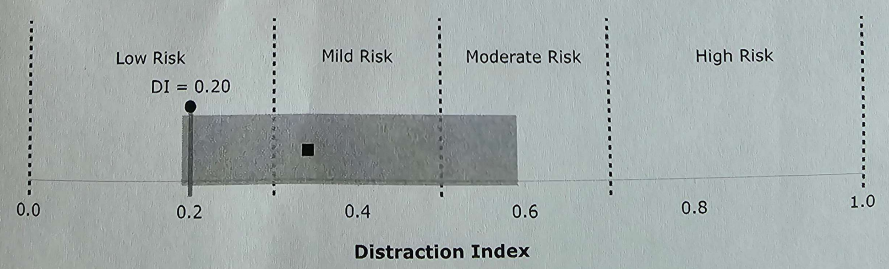

BREED STATISTICS: This interpretation is based on a cross-section of 1784 canine patients of the GERMAN SHORTHAIRED POINTER breed in the AIS PennHIP database. The gray strip represents the central 90% range of DIs (0.19
0.50) for the breed. The breed average DI is 0.34 (solid square). The patient DI is the solid circle (0.20).